

**PATIENT PRESENTING CLINICAL SIGNS**

Willis Molitoris

History: 2/6 murmur, pre surgical

**SPECIES ECHOCARDIOGRAPHIC FINDINGS**

Canine

2D, M-mode, and Doppler study.

**BREED**

Dachshund

Left atrial size is normal. The mitral valve leaflets are mildly thickened and exhibit mild systolic prolapse. A mild jet of eccentric mitral regurgitation is present. Left ventricular dimensions are normal. Left ventricular systolic function is hyperdynamic. The aorta and aortic valve are normal. Right atrial and right ventricular dimensions are normal. The tricuspid valve is normal. The pulmonary artery and pulmonic valve are normal. No shunting lesions are visualized. No pericardial effusion or cardiac masses are seen.

**SEX**

Male Neutered

LA - 29.3 mm  
LVIDd - 30.4 mm  
LVIDs - 14.6 mm  
FS - 52%  
LVOT - 1.59 m/s  
RVOT - 1.26 m/s

**AGE**

11 years

**WEIGHT**

26 lbs

**ELECTROCARDIOGRAPHIC FINDINGS**

A single lead ECG is submitted for review.

**INTERPRETED BY**

Keith Blass, DVM,  
MS, DACVIM

HR: 120 bpm  
Rhythm: Sinus arrhythmia

Sinus arrhythmia is present throughout this recording. All complex amplitudes and intervals are within normal limits. No premature beats or conduction blocks are seen.

**IMAGING PERFORMED BY**

Rebekah Jakum, CVT  
ARDMS/RVT

**ASSESSMENT/RECOMMENDATIONS**

Degenerative mitral valve disease

**HOSPITAL NAME**

New Britain VC

This examination demonstrates mild regurgitation of blood across Willis' mitral valve resulting from degenerative valve disease. The hemodynamic effects of the regurgitation also appear to be mild, as Willis does not have secondary dilation of either of his left heart chambers, and his left ventricular systolic function is well-preserved. As such, Willis' mitral valve disease appears to be well-compensated, and his current risk for the development of clinical signs secondary to it, such as coughing, exercise intolerance, syncope, and labored breathing, appears to be low.

**REFERRING VET**

Dr. Bandekar

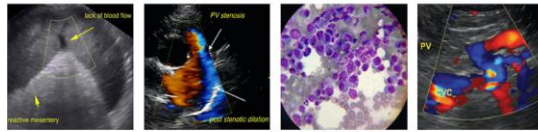
Willis' cardiovascular risk for general anesthesia is mildly increased based on this exam, therefore, some precautions should be taken in order to minimize this risk. I recommend avoiding the use of alpha-2 agonists in the anesthetic protocol, as well as reducing the IV fluid rate by 25%. If possible, monitoring of heart rhythm, blood pressure, and pulse oximetry are recommended during the procedure.

**DATE**

1.10.2022

No therapy is recommended at this stage of disease.

A recheck echocardiogram is recommended in ~6 months to monitor for disease progression.



**PATIENT**

Willis Molitoris

**SPECIES**

Canine

**BREED**

Dachshund

**SEX**

Male Neutered

**AGE**

11 years

**WEIGHT**

26 lbs

**INTERPRETED BY**

Keith Blass, DVM,  
MS, DACVIM

**IMAGING  
PERFORMED BY**

Rebekah Jakum, CVT  
ARDMS/RVT

**HOSPITAL NAME**

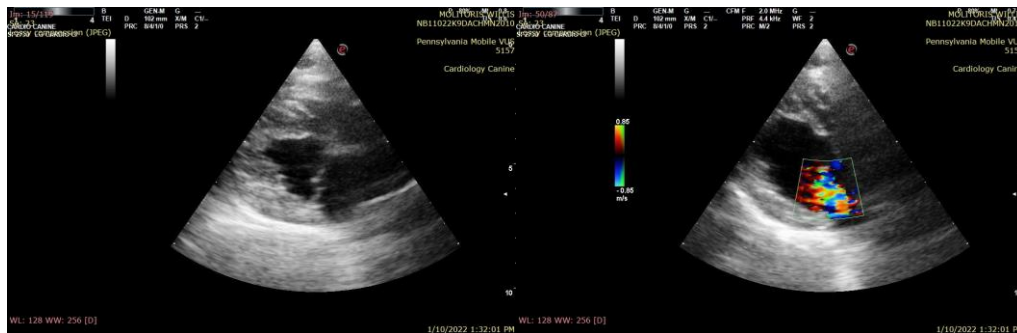New Britain VC

**REFERRING VET**

Dr. Bandekar

**DATE**

1.10.2022



The information and recommendations provided are based on the images presented by the referring veterinarian. No evaluation can be communicated regarding pathology that was not visible in the image/video clips provided.

Thank you for this referral. If the clinical or image interpretation does not parallel your findings or if I can be of any further assistance please contact me.

**Keith Blass, DVM, MS, DACVIM (Cardiology)**  
KeithBlass@gmail.com  
631-804-5754